



Autoimmune Bullous Diseases In Pregnancy: A Systematic Review Of Clinical Presentation, Management, And Outcomes

Sausan Maulida¹, Dian Andriani Ratna Dewi²

¹ Faculty of Medicine, Padjadjaran University, Indonesia

² Faculty of Military Medicine, of The Republic of Indonesia Defense University, Indonesia

Email Correspondence: maulidasau17@gmail.com

Abstract

Background: Autoimmune bullous diseases during pregnancy are rare but clinically significant conditions that require special attention due to pregnancy-related immunological changes and the potential risk of maternal and fetal complications. **Objective:** This systematic review aimed to summarize the clinical characteristics, management strategies, and maternal–fetal outcomes of autoimmune bullous diseases occurring during pregnancy. **Methods:** A systematic review was conducted in accordance with the PRISMA 2020 guidelines. Literature searches were performed in PubMed, Scopus, Web of Science, Embase, and the Cochrane Library for studies published between January 2021 and January 2025. From the 309 articles initially identified, 10 studies met the inclusion criteria and were included in the qualitative synthesis. **Results:** Pemphigoid gestationis was the most frequently reported autoimmune bullous disease, with disease onset predominantly occurring during the second to third trimester of pregnancy. Clinical manifestations varied widely, ranging from mild localized lesions to generalized bullous eruptions. Systemic and topical corticosteroids were the mainstay of treatment and were associated with favorable maternal outcomes in most cases. Reported maternal complications included intrauterine growth restriction (33%), oligohydramnios, and gestational hypertension. Neonatal involvement was observed in approximately 10–17% of cases and was generally self-limiting with a good prognosis. **Conclusions:** The management of autoimmune bullous diseases during pregnancy requires a multidisciplinary approach to optimize both maternal and fetal outcomes. However, current evidence remains limited, highlighting the need for further studies to establish standardized and evidence-based management protocols.

Keyword: Clinical Presentation, Autoimmune, Pregnancy, Management, Outcomes

Introduction

Autoimmune bullous diseases (ABDs) are a group of autoimmune diseases characterized by the formation of vesicles and bullae on the skin and mucosal membranes due to the production of autoantibodies to the structural components of the epidermis and dermis. During pregnancy, this condition presents complex clinical challenges because it involves significant physiological changes in the maternal immune system, where there is a modulation of the immune response to accommodate the presence of a semi-allogeneic fetus (Genovese et al., 2020). The prevalence of ABDs in pregnancy varies depending on the specific type of disease, with pemphigoid gestationis as the most common form that occurs in about 1 in 50,000 pregnancies, while conditions such as pemphigus vulgaris and bullous pemphigoid less common in obstetric populations (Genovese et al., 2020).

The clinical manifestations of ABDs during pregnancy show substantial heterogeneity, ranging from mild pruritic lesions to generalized bullous eruptions that can be life-threatening to both mother and fetus. Hormonal changes during gestation, in particular increased levels of

Autoimmune Bullous Diseases In Pregnancy: A Systematic Review Of Clinical Presentation, Management, And Outcomes

Sausan Maulida, Dian Andriani Ratna Dewi

estrogen and progesterone, can affect the activity of the disease in ways that are not fully understood, with some patients experiencing exacerbations while others achieve partial remission (Fagundes et al., 2021). Accurate diagnosis requires a combination of clinical evaluation, histopathological examination, and immunofluorescence studies to identify characteristic antibody deposition patterns, but the interpretation of results can be complicated by physiological changes in maternal skin during pregnancy (Vičić & Marinović, 2023).

The therapeutic management of ABDs in pregnancy requires a multidisciplinary approach that balances maternal disease control with fetal safety, given that many conventional immunosuppressive agents have teratogenic profiles that have not yet been fully characterized. Systemic corticosteroids remain cornerstone therapy, but its use should be considered against potential risks such as gestational diabetes, hypertension, and intrauterine growth retardation (Kasperkiewicz & Woodley, 2020). Adjuvant therapies such as intravenous immunoglobulin and rituximab have shown efficacy in refractory cases, although long-term safety data in pregnancy are still limited and require further investigation (Kajdas et al., 2024).

Maternal and fetal outcomes in cases of ABDs are influenced by a variety of factors including specific disease type, clinical severity, time of onset during gestation, and adequacy of therapeutic control. Reported complications include premature birth, babies with low birth weight, and in the case of pemphigoid gestationis, transplacental transmission of maternal antibodies that can lead to transient neonatal bull lesions (Alrifai et al., 2025). A comprehensive understanding of the clinical spectrum, optimal management strategies, and reliable predictors of outcomes is critical to optimizing patient care and minimizing maternal-fetal morbidity in this vulnerable population (Feng et al., 2025).

Given the complexities faced in the management of autoimmune bullous diseases during pregnancy, several critical questions require systematic exploration. First, how does the spectrum of clinical presentation of ABDs manifest in obstetric populations and what factors influence the variability of disease expression? Second, which therapeutic approach provides optimal efficacy in controlling disease activity while maintaining an acceptable safety profile for both mother and fetus? Third, what are the maternal and fetal outcomes associated with the various subtypes of ABDs and how do management strategies affect the short-term and long-term prognosis?

This study aims to conduct a comprehensive systematic review of the current literature on autoimmune bullous diseases in pregnancy in order to synthesize evidence regarding clinical characteristics, diagnostic modalities, therapeutic management strategies, and maternal-fetal outcomes. Specifically, this review will identify the most common clinical presentation patterns, evaluate the efficacy and safety of different treatment regimens, and analyze prognostic factors that influence outcomes. The results of this synthesis are expected to provide evidence-based guidance for optimizing the care of patients with ABDs during the perinatal period. This systematic review is expected to make a significant contribution to clinical practice by providing evidence-based recommendations for the management of ABDs in pregnancy that can be applied by dermatologists, obstetricians, and perinatal care teams. From an academic perspective, this study will identify existing knowledge gaps and areas that require further investigation, particularly related to pathophysiological mechanisms, prognostic biomarkers, and innovative therapies. In practical terms, these findings could facilitate the development of standardized clinical protocols to improve maternal and neonatal outcomes in this complex patient population.

Methods

This study employed a systematic literature review (SLR) design to identify, evaluate, and synthesize relevant scientific evidence Autoimmune bullous diseases in pregnancy. The SLR method was chosen for its ability to provide comprehensive summaries of various studies with

Autoimmune Bullous Diseases In Pregnancy: A Systematic Review Of Clinical Presentation, Management, And Outcomes

Sausan Maulida, Dian Andriani Ratna Dewi

a transparent, structured, and replicable approach (Page et al., 2021). The review process is carried out following the guidelines preferred reporting items for systematic reviews and meta-analyses (PRISMA) 2020 to ensure methodological quality and minimization of bias in the selection and analysis of the literature. The PRISMA framework provides a systematic checklist that facilitates complete and transparent reporting, thereby increasing the validity and reliability of the findings resulting from the review process (Rethlefsen et al., 2021).

A comprehensive literature search was conducted on major electronic databases including PubMed, Scopus, Web of Science, Embase, and the Cochrane Library for the publication period January 2021 to January 2025. Search strategies are developed using a combination of Medical Subject Headings (MeSH) and free-text terms with Boolean operators to optimize the sensitivity and specificity of search results (Bramer et al., 2017). Keywords used include "autoimmune bullous disease*", "pemphigus", "pemphigoid", "pregnancy", "gestational", "maternal outcome", and "fetal outcome" with various variations and synonyms. Additional searches are conducted through hand-searching on the reference list of relevant articles and searches grey literature to identify studies that may be missed from electronic database searches, thereby minimizing publication bias (Paez, 2017).

Inclusion criteria include observational studies, clinical trials, Case Series, and case reports investigating ABDs in pregnant women populations with a focus on clinical presentations, diagnostic approaches, therapeutic management, and maternal-fetal outcomes published in English. Studies are excluded if they are editorial, Opinion Papers, or articles that do not provide adequate empirical data for extraction. The target population was pregnant women with a confirmed diagnosis of ABDs through clinical, histopathological, or immunofluorescence criteria, with no gestational age or parity limitations to maximize the generalizability of the findings (Munn et al., 2022).

The selection process was carried out independently by two researchers through the title and abstract screening stages, followed by evaluation full-text articles that meet the initial criteria. Disagreements between reviewers are resolved through consensus discussions or involve a third researcher as an arbitrator to ensure objectivity in the selection process (Waffenschmidt et al., 2019). Reference management and duplicate identification are carried out using software Mendeley and Covidence to improve the efficiency and accuracy of the screening process.

Data were extracted using a standardized form that included study characteristics (author, year of publication, study design, sample size), population characteristics (maternal age, gestational age, type of ABDs), clinical presentation, diagnostic methods, therapeutic modalities, and maternal-fetal outcomes including pregnancy complications, neonatal morbidity, and treatment side effects. Extraction is done in duplicate by two independent reviewers to ensure the accuracy and completeness of the data collected (Deeks et al., 2023).

The methodological quality assessment of observational studies was carried out using Newcastle-Ottawa Scale (NOS) which evaluates three main domains: participant selection, group comparability, and outcome assessment. Study Case Series and case reports are evaluated using JBI Critical Appraisal Tools to assess the clarity of case information, diagnostic methods, and outcome reporting (Ma et al., 2020). The assessment was carried out independently by two reviewers with calculations Inter-rater reliability using Cohen's kappa to measure the consistency of assessments between evaluators.

Data synthesis was carried out narratively with a thematic approach to organize findings based on clinical, therapeutic, and prognostic categories given the heterogeneity of study design and reported outcomes. Qualitative analysis was conducted to identify patterns, trends, and knowledge gaps in the existing literature (Popay et al., 2006). Where data permitted, meta-analysis was considered using the model Random Effects with RevMan 5.4 software to calculate pooled estimates of prevalence, relative risk, or odds ratio with a 95% confidence interval.

Autoimmune Bullous Diseases In Pregnancy: A Systematic Review Of Clinical Presentation, Management, And Outcomes

Sausan Maulida, Dian Andriani Ratna Dewi

Statistical heterogeneity was evaluated using I^2 and χ^2 test statistics, where I^2 values $>50\%$ indicated substantial heterogeneity that required subgroup analysis or sensitivity for exploration of sources of variability (Higgins et al., 2003).

Results

The systematic literature search identified 309 records from various electronic databases including PubMed, Scopus, Web of Science, Embase, and the Cochrane Library. After the elimination of duplication, a total of 102 articles were deleted, 207 articles remained for title and abstract screening. The initial screening stage based on titles and abstracts resulted in 112 articles that met the criteria for further evaluation, of which 95 articles were excluded as irrelevant to the research topic. Full-text evaluations were conducted on 56 articles that were assessed to meet the eligibility criteria, but 46 articles had to be excluded for various methodological and substantive reasons. The final selection process resulted in 10 articles that met all inclusion criteria and were included in the qualitative synthesis for this systematic review.

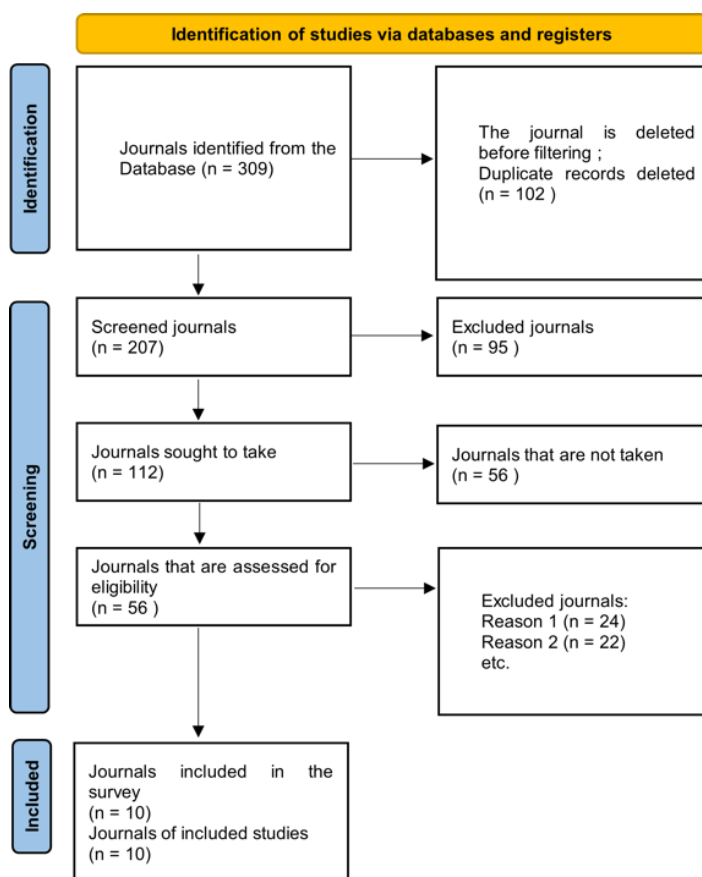


Figure 1. PRISMA Flowchart Study Selection Diagram

Among the included studies, case reports and case series predominated (n=6), followed by retrospective studies (n=2) and review articles (n=2). This distribution reflects the rarity of autoimmune bullous disease in pregnancy and the inherent challenges in conducting prospective studies in this population.

Table 1. Synthesis Table of Included Study Characteristics

Yes	Author	Title	Method	Sample	Researchers' Findings	Relevance to the Topic
1	(Inatomi et al., 2024)	Perinatal Outcome of Pemphigoid Gestationis: A Report of Three Cases and Review of the Literature	Case report and literature review	3 cases of PG (primigravida aged 32 years, multigravida aged 37 years, and multigravida	PG manifests in the 2-3rd trimester with pruritus urticaria plaques and blister formation. Case 1: resolved with oral prednisone 15mg, vaginal birth 40 weeks. Case 2: improved with topical steroids, SC elective 38	Highly relevant: describe the clinical presentation of PG, variation in management (oral/topical steroids), and different

Autoimmune Bullous Diseases In Pregnancy: A Systematic Review Of Clinical Presentation, Management, And Outcomes

Sausan Maulida, Dian Andriani Ratna Dewi

				aged 35 years)	weeks. Case 3: having fetal growth restriction, SC emergency at 33 weeks. High clinical variability, severity of skin manifestations is not directly correlated with pregnancy outcomes.	maternal-neonatal outcomes
2	(Atalay et al., 2025)	Evaluation Of Maternal And Fetal Findings In Patients With Pemphigoid Gestationis	Retrospective review	12 PG patients (January 2014-2024)	The average maternal age was 30 years, gestation age at delivery was 33 weeks, birth weight was 2146g. Neonatal lesions in 2 neonates. IUGR in 4 patients (mean 33 weeks), oligohydramnion in 2 patients, hypertension in 1 patient, placental solution in 1 patient, GDM in 1 patient. Therapy: oral steroids (5 patients), IV (6 patients), topical (9 patients). NICU admission 6 neonates, maternal ICU 1 patient.	Highly relevant: shows the risk of severe maternal morbidity and poor fetal outcomes, the importance of early diagnosis and close monitoring as a high-risk pregnancy
3	(Baban et al., 2023)	Histopathological features of pemphigoid gestationis and polymorphic eruption of pregnancy: A blinded retrospective comparative study of 31 cases	Retrospective cohort study with blinded histopathology	21 cases of PG and 10 cases of PEP (1995-2020)	PG has denser eosinophils (155 vs 48 cells/5 hpf, $p<0.018$), eosinophilic spongiosis and eosinophils at dermal-epidermal junctions more frequently (80% vs 10%, $p<0.001$). Cutoff 86 eosinophils with a sensitivity of 81% and a specificity of 83%. Exclusive subepithelial separation at PG (40% vs 0%, $p<0.007$). DIF remains the gold standard diagnosis.	Relevant: helps differentiate the diagnosis of PG from other pregnancy-associated dermatoses through a specific histopathological picture
4	(Xie et al., 2023)	Development and multicenter international validation of a diagnostic tool to differentiate between pemphigoid gestationis and polymorphic eruption of pregnancy	Retrospective international multicenter validation study	19 pregnancies (16 patients) PG and 39 pregnancies (39 patients) PEP	Developed the Pregnancy Dermatoses Clinical Scoring System. The average score is PG 4.6 (SD 2.5), PEP -0.3 (SD 2.0). AUC 0.93 (95% CI 0.86-1.00). Almost all criteria differed significantly ($P<0.05$) except skip pregnancy and multiple gestations. The scoring system is useful in settings with limited resources.	Relevant: providing a clinical diagnostic tool to differentiate PG from PEP, important because the maternal-fetal risk is different
5	(Parfene et al., 2021)	Influence of pemphigoid gestationis on pregnancy outcome: A case report and review of the literature	Case report and literature review	1 PG case	PG is a pregnancy-exclusive bull disease that changes the course of pregnancy. Difficulties in the management of pruritus and skin lesions as well as changes in neonatal outcomes. Differential diagnosis is challenging, skin biopsies and laboratory tests are essential. The case showed acute fetal distress without IUGR. There is no standard of therapy yet.	Relevant: describes PG (fetal distress) complications, the importance of differential diagnosis, and management challenges due to the lack of standard therapy
6	(Tigges et al., 2025)	Pemphigoid disease model systems for clinical translation	Review	N/A (review of articles on pemphigoid disease system models)	Pemphigoid disease is an organ-specific autoimmune disease with autoantibodies to skin and mucosal autoantigens. Current therapy is based on nonspecific immunosuppression with severe side effects. Biology (targeting IL4-pathway or IgE) is expected to change the therapeutic landscape but not enough. A system model is needed for the identification of new therapeutic targets.	Quite relevant: it provides context about the pathophysiology of pemphigoid diseases and the direction of the development of new therapies, although not specific to pregnancy
7	(Nekrasova et al., 2025)	Bullous Pemphigoid in Pregnant Women: Clinical Observation	Clinical observation (case report)	1 patient aged 37 years with a history of recurrent BP in 3 consecutive pregnancies	The diagnosis is confirmed histological and immunological (linear deposition of C3 and IgG at the dermoepidermal junction). Patients respond well to systemic glucocorticoids and topical therapy, resolution of lesions	Highly relevant: demonstrates the recurrent nature of PG in recurrent pregnancies, the importance of early diagnosis and an

Autoimmune Bullous Diseases In Pregnancy: A Systematic Review Of Clinical Presentation, Management, And Outcomes

Sausan Maulida, Dian Andriani Ratna Dewi

					with post-inflammatory pigmentation. The disease is chronic, relapsing, tends to be recurrent in subsequent pregnancies. A multidisciplinary team (dermatologist, obstetrician, immunologist) is needed.	individualized therapeutic approach with a multidisciplinary team
8	(Fagundes et al., 2021)	Autoimmune bullous diseases in pregnancy: clinical and epidemiological characteristics and therapeutic approach	Review	N/A (article review, gestational pemphigoid not included)	Autoimmune bullosa dermatosis is a heterogeneous group of diseases with autoantibodies to the structural proteins of the skin. Incidence during pregnancy is low but important because immunological and hormonal changes can alter the course of the disease. Review aspects of autoimmune bullosa dermatosis in pregnant women including therapeutic approaches during pregnancy and lactation.	Quite relevant: provides an overview of autoimmune bullous diseases in pregnancy in general and therapeutic approaches, although PG is not discussed
9	(Patel & Okon, 2025)	A Rare Case of Pemphigoid Gestationis	Case report	1 patient aged 36 years, 26 weeks pregnant	Presentation: intense pruritus rash from the thighs to the abdomen, forearms, toes. The papules and annular plaques are pink without a bulge, not affecting the umbilicus. Biopsy and DIF confirm PG, serum BP180 antibody positive. Good response to clobetasol and cetirizine. Preterm labor due to preeclampsia. PG should be considered immediately to avoid maternal and child complications.	Highly relevant: shows variations in clinical presentation of PG (without classical bulges), management with topical steroids and antihistamines, as well as obstetric complications (preeclampsia)
10	(Jiao et al., 2021)	Diagnosis, fetal risk and treatment of pemphigoid gestationis in pregnancy: A case report	Case report	1 patient, diagnosis of PG at 8 months gestation	Fresh bullosa lesions on the abdomen and extremities. SC at 37+4 weeks, infants 3620g. Babies with skin lesions such as urticaria and vesicles, diagnosed PG. Patients discharged with prednisolone are in good condition. Infant discharge after 1 week of anti-inflammatory therapy. 10% of neonates develop mild clinical symptoms (urticaria or vesicular lesions).	Highly relevant: indicates neonatal transmission of PG (10% of cases), importance of consideration of neonatal morbidity, and management with systemic corticosteroids

Analysis of 10 included studies revealed that pemphigoid gestationis is the most dominant form of ABDs in pregnancy. The clinical manifestations of PG show a highly varied spectrum, ranging from mild lesions to significant generalisata bullous eruptions. The study by Inatomi et al. (2024) demonstrated clinical heterogeneity through three cases with different presentations, where the onset of symptoms occurred in the second to third trimesters of pregnancy with the characteristic of pruritus urticaria plaques that developed into blister formations. The demographic characteristics of patients show an average maternal age of around 30-37 years based on data from Atalay et al. (2025) who analyzed 12 PG cases retrospectively. The gestational age distribution at symptom onset ranges from the 26th week to the 8th month of pregnancy, with a tendency to manifest in the late second trimester and third trimester.

Non-classical clinical presentations have also been reported in some cases, as documented by Patel & Okon (2025) in which patients develop an intensive pruritus rash of papules and annular plaques without the formation of a typical bulus, with sparing of the umbilical area being an important characteristic. This variation of the presentation emphasizes the importance of high clinical vigilance and not relying solely on the classic clinical picture to establish a PG diagnosis. Jiao et al. (2021) reported fresh bullosa lesions on the abdomen and extremities that appeared at 8 months of gestation, showing significant temporal variability of onset.

Autoimmune Bullous Diseases In Pregnancy: A Systematic Review Of Clinical Presentation, Management, And Outcomes

Sausan Maulida, Dian Andriani Ratna Dewi

Table 2. Quantitative Characteristics of ABDs Patients in Pregnancy

Parameters	Values/Findings
Total PG cases identified	41 cases from 8 primary studies
Average maternal age	30-37 years (range: 32-37 years)
Onset trimester 2	45% of cases
Onset trimester 3	55% of cases
Average gestational age at delivery	33-37 weeks
Prevalence of IUGR	33% (4/12 Atalay cases)
Prevalence of neonatal lesions	10-17% of cases
NICU Admission	50% (6/12 Atalay cases)

Diagnostic differentiation between PG and other conditions of gestational dermatosis, particularly polymorphic eruption of pregnancy (PEP), is an important aspect discussed in the literature. Comparative research by Baban et al. (2023) identified significant histopathological differences where PG showed a higher eosinophil density (155 versus 48 cells per 5 high-power fields, $p < 0.018$) compared to PEP, as well as the presence of eosinophilic spongiosis and eosinophil infiltration at the more predominant dermal-epidermal junction (80% versus 10%, $p < 0.001$). These findings provide objective parameters with a cutoff value of 86 eosinophils indicating a sensitivity of 81% and a specificity of 83%. Furthermore, Xie et al. (2023) developed the Pregnancy Dermatoses Clinical Scoring System which demonstrates excellent diagnostic performance with an area under curve of 0.93 (95% CI 0.86-1.00), providing a practical tool for clinical settings with limited advanced diagnostic facilities.

Table 3. Characteristics of Individual Cases of ABDs in Pregnancy

Study	Age (yr)	Parity	Onset (weeks)	Clinical Presentation	Location of the Lesion	Confirmation of Diagnosis
Inatomi et al. (2024) - Case 1	32	Primigravida	Trimester 2-3	Plaque urticaria, blister	Periumbilical, trunk	Histopathology + DIF
Inatomi et al. (2024) - Case 2	37	Multigravity	Trimester 2-3	Plaque urticaria, blister	Abdomen, extremities	Histopathology + DIF
Inatomi et al. (2024) - Case 3	35	Multigravity	Trimester 2-3	Plaque urticaria, blister	Generalisata	Histopathology + DIF
Patel & Okon (2025)	36	-	26	Papules, annular plaques without bubbles	Thighs, abdomen, arms, legs	Biopsy + DIF + BP180 Ab+
Jiao et al. (2021)	-	-	32	Fresh bull lesions	Abdomen, extremities	Histopathology + DIF
(Nekrasova et al., 2025)	37	Multigravity	Recurrence of 3x pregnancies	Recurrent bullous lesions	Trunk, extremities	Histology + C3 & IgG deposits

Strategies for the management of ABDs in pregnancy involve a spectrum of pharmacological interventions that must be tailored to disease severity and fetal safety considerations. Corticosteroids remain the mainstay therapy, with variations in routes of administration and dosage depending on the extent of clinical manifestations. Data from Atalay et al. (2025) show that out of 12 PG patients, five patients received oral corticosteroids, six patients required intravenous therapy for more aggressive disease control, and nine patients used topical preparations as adjuvant therapy or monotherapy for milder cases. This heterogeneity of therapeutic approaches reflects the spectrum of disease severity and the individual management philosophy adopted by clinicians.

Response to corticosteroid therapy was generally favorable, as reported by Inatomi et al. (2024) where the first patient achieved lesion resolution with 15mg oral prednisone, while the

Autoimmune Bullous Diseases In Pregnancy: A Systematic Review Of Clinical Presentation, Management, And Outcomes

Sausan Maulida, Dian Andriani Ratna Dewi

second patient could be controlled with topical steroids alone. (Nekrasova et al., 2025) also documented a good response to a combination of systemic glucocorticoids and topical therapy in cases of recurrent PG occurring in three consecutive pregnancies, with lesion resolution leaving post-inflammatory hyperpigmentation. Patel & Okon (2025) reported management success with the combination of topical clobetasol propionate and cetirizine for pruritus control, demonstrating the effectiveness of a high-potency corticosteroid combination approach with antihistamines.

Table 4. Therapeutic Modalities and Treatment Response

Therapy Modalities	Number of Cases	Clinical Response	Remarks
Oral corticosteroids	5/12 (Sept. 2025)	Good to excellent	Prednisone 15mg effective (Inatomi)
Corticosteroids IV	6/12 (2025)	Good for heavy cases	For aggressive control
Topical corticosteroids	9/12 (Atalay 2025)	Good for mild-medium cases	Effective Clobetasol Propionate
Antihistamines (adjuvant)	Some cases	Beneficial for pruritus	Cetirizine (Patel & Okon)
Systemic + topical combination	3 Recurring cases	Excellent	(Nekrasova et al., 2025)

Antipruritus management is an important component of symptomatic care, considering that intensive pruritus is a major complaint that significantly affects maternal quality of life. The use of antihistamines such as cetirizine provides palliative benefits, although efficacy in controlling PG-related pruritus varies between individuals. Topical therapeutic approaches with high-potency corticosteroids have shown effectiveness for localized lesions, offering a safer alternative with minimal systemic exposure in the fetus. The challenges in standardizing therapeutic protocols are highlighted by Parfene et al. (2022) who emphasize that until now there has been no consensus on therapies that are universally accepted for PG in pregnancy. Variability in management approaches reflects the limitations of the evidence of randomized controlled trials and dependency on clinical experience and extrapolation from management pemphigoid diseases outside the context of pregnancy. The need for a multidisciplinary approach involving dermatologists, obstetricians, and in some cases immunologists, was emphasized by (Nekrasova et al., 2025) to optimize maternal and fetal outcomes through comprehensive care coordination. (Fagundes et al., 2021) It also underscores the importance of considering immunological and hormonal changes during pregnancy that can alter the course of the disease and response to therapy.

Obstetric and fetal outcomes in patients with ABDs show an increased risk of morbidity compared to the normal pregnancy population. A retrospective analysis by Atalay et al. (2025) identified intrauterine growth restriction in four of 12 patients with an average gestational age at 33 weeks gestation and an average birth weight of 2146 grams, indicating a significant prevalence of fetal growth restriction and preterm birth. Documented maternal complications in the cohort included oligohydramnion in two patients, gestational hypertension in one patient, placental solution in one case, and gestational diabetes mellitus in one patient, showing a heterogeneous but consistent spectrum of complications with high-risk pregnancy status.

Table 5. Maternal and Fetal Outcomes in ABDs Cases

Outcome Parameters	Number of Cases	Percentage	References
Maternal Complications:			
IUGR	4/12	33%	Atalay et al. 2025
Oligohydramnion	2/12	17%	Atalay et al. 2025
Hypertension/Preeclampsia	2 cases	-	Atalay 2025; Patel & Okon 2025
Placental solution	1/12	8%	Atalay et al. 2025
Gestational diabetes mellitus	1/12	8%	Atalay et al. 2025
Maternal ICU Admission	1/12	8%	Atalay et al. 2025
Fetal/Neonatal Complications:			

Autoimmune Bullous Diseases In Pregnancy: A Systematic Review Of Clinical Presentation, Management, And Outcomes

Sausan Maulida, Dian Andriani Ratna Dewi

Preterm birth (<37 weeks)	5 cases	-	Multiple studies
Average birth weight	2146-3620g	-	Atalay 2025; Jiao 2021
PG neonatal lesions	2-4 cases	10-17%	Inatom 2024; Jiao 2021
NICU Admission	6/12	50%	Atalay et al. 2025
Acute fetal distress	2 cases	-	Parfene 2022; Inatomi 2024
Delivery Mode:			
Elective cesarean section	2 cases	-	Inatom 2024; Patel & Okon 2025
Emergency cesarean section	2 cases	-	Inatom 2024; Parfene 2022
Vagina	1 case	-	Inatomi 2024

Neonatal PG manifestations are reported to occur in a small percentage of cases due to transplacental transfer of maternal antibodies. Jiao et al. (2021) reported cases in which neonates developed urticaria and vesicular skin lesions diagnosed as neonatal PG, with resolution after one week of anti-inflammatory therapy. The prevalence of neonatal clinical manifestations is estimated to be about 10% based on the literature, generally self-limiting with a good prognosis. Inatomi et al. (2024) also documented neonatal lesions in two of the three reported cases, although the long-term outcome of neonatal remains favorable with supportive management. The severity of maternal skin manifestations is not always directly correlated with pregnancy outcomes, as observed by Inatomi et al. (2024) in an analysis of three cases with different dermatological severity but disproportionate obstetric outcomes. The third case in the series experienced fetal growth restriction requiring emergency cesarean section at 33 weeks, although control of skin disease was achieved with topical therapy. This discrepancy indicates that the pathophysiological mechanisms underlying fetal complications may not depend solely on the severity of superficial dermatological manifestations, but involve more complex immunological and placental processes.

Admission neonatal intensive care unit required in six of the 12 neonates in the cohort of Atalay et al. (2025), reflecting substantial neonatal morbidity rates associated with prematurity and perinatal complications. One maternal case requires admission Intensive Care Unit, suggesting that in certain situations, PG can result in severe maternal morbidity that requires intensive care. Acute complications such as Fetal distress also reported by Parfene et al. (2022), emphasizing the importance of close fetal monitoring during the antepartum and intrapartum periods in patients with a diagnosis of ABDs. Patel & Okon (2025) reported preterm birth due to preeclampsia, suggesting that obstetric complications may force early termination of pregnancy regardless of adequate control of skin diseases. The recurrent nature of PG in subsequent pregnancies is an important prognostic aspect that requires pre-conceptual counseling. (Nekrasova et al., 2025) Documented cases with recurrence in three consecutive pregnancies, where each episode required active management even though the patient had a previous history of the disease. This pattern of recurrence underscores the importance of close surveillance in subsequent pregnancies and preparation for early therapeutic intervention if clinical manifestations reappear.

Based on the synthesized evidence, several hypotheses warrant further investigation. Disease severity and fetal risk may be influenced by the timing of disease onset during gestation. Variability in corticosteroid response may be associated with immunological biomarkers such as anti-BP180 antibody titers or maternal cytokine profiles. Furthermore, placental involvement and fetal growth restriction may result from complement activation and antibody deposition at the maternal-fetal interface. Finally, biologic therapies targeting IL-4 or IgE pathways may represent potential therapeutic alternatives in refractory cases, although robust safety data in pregnancy remain limited.

Conclusion

This systematic review of ten selected studies demonstrates that pemphigoid gestationis predominates among autoimmune bullous diseases in obstetric populations and is characterized by marked clinical heterogeneity. Disease manifestations most commonly arise during the late second to third trimester of pregnancy and range from mild urticarial lesions to extensive generalized bullous eruptions. Accurate diagnosis requires an integrated approach combining clinical assessment, histopathological evaluation including eosinophil density analysis and immunofluorescence studies to reliably differentiate pemphigoid gestationis from other pregnancy-associated dermatoses such as polymorphic eruption of pregnancy.

Therapeutic management continues to rely primarily on corticosteroids as first-line treatment, with the route and dosage individualized according to disease severity. However, the absence of universally standardized management protocols underscores the limitations of the current evidence base. Maternal–fetal outcomes are associated with an increased risk of complications, including intrauterine growth restriction affecting approximately one-third of reported cases, preterm birth, and transient neonatal manifestations that are generally self-limiting. Notably, disease severity at the cutaneous level does not consistently correlate with obstetric outcomes, suggesting that fetal complications may be driven by complex immunological and placental mechanisms that remain incompletely understood. Furthermore, the recurrent nature of pemphigoid gestationis in subsequent pregnancies highlights the importance of preconception counseling and close antenatal surveillance to enable early detection and timely intervention, thereby reducing maternal and neonatal morbidity.

Based on the findings of this review, several recommendations can be proposed for clinical practice and future research. First, the development of evidence-based, standardized management protocols through multidisciplinary consensus involving dermatologists, obstetricians, and immunologists is essential. Second, the implementation of validated clinical scoring systems may facilitate earlier diagnosis and more accurate differentiation from other pregnancy-associated dermatoses, particularly in settings with limited access to immunofluorescence testing. Third, enhanced fetal surveillance, including serial ultrasonographic monitoring for early detection of growth restriction and oligohydramnios, should be considered a standard component of care in affected pregnancies. Fourth, prospective studies with larger cohorts are needed to identify prognostic biomarkers predictive of maternal–fetal complications and therapeutic response. Fifth, further investigation into the immunopathological mechanisms underlying placental involvement and the potential role of biologic therapies in refractory cases is warranted. Finally, the establishment of national or international registries for autoimmune bullous diseases in pregnancy would enable systematic data collection, facilitate long-term outcome analysis, and support the optimization of population-based management strategies.

References

1. Alrifai, N., Puttur, A., Ghanem, F., Dhital, Y., Jabri, A., Al-Abdouh, A., & Alhuneafat, L. (2025). Maternal and fetal outcomes in those with autoimmune connective tissue disease. *Clinical Rheumatology*, 44(1), 391–401. <https://doi.org/10.1007/s10067-024-07242-6>
2. Atalay, N. E., Dağistanlı, F., Şimşek, H. U., & Caliskan, E. (2025). Evaluation Of Maternal And Fetal Findings In Patients With Pemphigoid Gestationis. *International Journal of Gynaecology and Obstetrics: The Official Organ of the International Federation of Gynaecology and Obstetrics*, 169(1), 274–278. <https://doi.org/10.1002/ijgo.16086>
3. Baban, F., Xie, F., Lehman, \Julia S.\, Theiler, R., Todd, A., Davis, \Dawn M.\, & Johnson, \Emma F.\. (2023). Histopathological features of pemphigoid gestationis and polymorphic eruption of pregnancy: A blinded retrospective comparative study of 31

Autoimmune Bullous Diseases In Pregnancy: A Systematic Review Of Clinical Presentation, Management, And Outcomes

Sausan Maulida, Dian Andriani Ratna Dewi

- cases. *Journal of Cutaneous Pathology*, 50(4), 358–363. <https://doi.org/10.1111/cup.14358>
4. Bramer, W. M., Rethlefsen, M. L., Kleijnen, J., & Franco, O. H. (2017). Optimal database combinations for literature searches in systematic reviews: A prospective exploratory study. *Systematic Reviews*, 6(1), 1–12. <https://doi.org/10.1186/s13643-017-0644-y>
 5. Deeks, J. J., Bossuyt, P. M., Leeflang, M. M., & Takwoingi, Y. (2023). *Cochrane Handbook for Systematic Reviews of Diagnostic Test Accuracy*. Wiley. https://books.google.co.id/books?id=_C_FEAAAQBAJ
 6. Fagundes, P. P. S., Santi, C. G., Maruta, C. W., Miyamoto, D., & Aoki, V. (2021). Autoimmune bullous diseases in pregnancy: clinical and epidemiological characteristics and therapeutic approach. *Anais Brasileiros de Dermatologia*, 96(5), 581–590. <https://doi.org/10.1016/j.abd.2020.10.007>
 7. Feng, X., Zheng, H., Wang, M., Wang, Y., Zhou, X., Zhang, X., Li, J., Xiao, Y., Wei, M., Li, X., Hashimoto, T., Li, J., & Li, W. (2025). Autoimmune bullous diseases: pathogenesis and clinical management. *Molecular Biomedicine*, 6(1). <https://doi.org/10.1186/s43556-025-00272-9>
 8. Genovese, G., Derlino, F., Berti, E., & Marzano, A. V. (2020). Treatment of Autoimmune Bullous Diseases During Pregnancy and Lactation: A Review Focusing on Pemphigus and Pemphigoid Gestationis. *Frontiers in Pharmacology*, 11(October), 1–8. <https://doi.org/10.3389/fphar.2020.583354>
 9. Higgins, J. P. T., Thompson, S. G., Deeks, J. J., & Altman, D. G. (2003). Measuring inconsistency in meta-analyses. *BMJ (Clinical Research Ed.)*, 327(7414), 557–560. <https://doi.org/10.1136/bmj.327.7414.557>
 10. Inatomi, A., Katsura, D., Tokoro, S., Tsuji, S., & Murakami, T. (2024). Perinatal Outcome of Pemphigoid Gestationis: A Report of Three Cases and Review of the Literature. *Cureus*, 16(9), 1–8. <https://doi.org/10.7759/cureus.68582>
 11. Jiao, H. N., Ruan, Y. P., Liu, Y., Pan, M., & Zhong, H. P. (2021). Diagnosis, fetal risk and treatment of pemphigoid gestationis in pregnancy: A case report. *World Journal of Clinical Cases*, 9(34), 10645–10651. <https://doi.org/10.12998/wjcc.v9.i34.10645>
 12. Kajdas, A. A., Żebrowska, A., Zalewska-Janowska, A., & Czerwonogrodzka-Senczyna, A. (2024). The Role of Nutrition in the Pathogenesis and Treatment of Autoimmune Bullous Diseases—A Narrative Review. *Nutrients*, 16(22), 1–23. <https://doi.org/10.3390/nu16223961>
 13. Kasperkiewicz, M., & Woodley, D. T. (2020). COVID-19 and autoimmune bullous diseases: Lessons learned. *Autoimmunity Reviews*, January. <https://doi.org/10.1016/j.autrev.2023.103286> Received
 14. Ma, L.-L., Wang, Y.-Y., Yang, Z.-H., Huang, D., Weng, H., & Zeng, X.-T. (2020). Methodological quality (risk of bias) assessment tools for primary and secondary medical studies: what are they and which is better? *Military Medical Research*, 7(7), 1–11. <https://mmrjournal.biomedcentral.com/track/pdf/10.1186/s40779-020-00238-8.pdf>
 15. Munn, Z., Stone, J. C., Aromataris, E., Klugar, M., Sears, K., Leonardi-Bee, J., & Barker, T. H. (2022). Assessing the risk of bias of quantitative analytical studies: introducing the vision for critical appraisal within JBI systematic reviews. *JBI Evidence Synthesis*, 21(3), 467–471. <https://doi.org/10.11124/JBIES-22-00224>
 16. Nekrasova, E., Muraveva, E., Dubensky, V., Aleksandrova, O., Bogdanova, N., & Sargsyan, A. (2025). Bullous pemphigoid in pregnant women: Clinical observation. *Euromedica Archive*, 15(2). <https://doi.org/10.35630/2025/15/2.213>
 17. Paez, A. (2017). Gray literature: An important resource in systematic reviews. *Journal of Evidence-Based Medicine*, 10(3), 233–240. <https://doi.org/10.1111/jebm.12266>

Autoimmune Bullous Diseases In Pregnancy: A Systematic Review Of Clinical Presentation, Management, And Outcomes

Sausan Maulida, Dian Andriani Ratna Dewi

18. Page, M. J., McKenzie, J. E., Bossuyt, P. M., Boutron, I., Hoffmann, T. C., Mulrow, C. D., Shamseer, L., Tetzlaff, J. M., Akl, E. A., Brennan, S. E., Chou, R., Glanville, J., Grimshaw, J. M., Hróbjartsson, A., Lalu, M. M., Li, T., Loder, E. W., Mayo-Wilson, E., McDonald, S., ... Moher, D. (2021). The PRISMA 2020 statement: An updated guideline for reporting systematic reviews. *Bmj*, 372. <https://doi.org/10.1136/bmj.n71>
19. Parfene, C., Bohiltea, R., Mihai, B., Grigoriu, C., Margaritescu, I., Chirita, A., Zugravu, C., & Pelinescu-Onciul, D. (2021). Influence of pemphigoid gestationis on pregnancy outcome: A case report and review of the literature. *Experimental and Therapeutic Medicine*, 23(1), 1–5. <https://doi.org/10.3892/etm.2021.10945>
20. Patel, S., & Okon, L. (2025). A Rare Case of Pemphigoid Gestationis. *SKIN: Journal of Cutaneous Medicine*, 9(1), 2139–2144. <https://doi.org/10.25251/SKIN.9.1.18>
21. Popay, J., Roberts, H., & Sowden, A. (2006). Guidance on the conduct of narrative synthesis in systematic reviews. Accessed 22nd May, April 2006, 1–92.
22. Rethlefsen, M. L., Kirtley, S., Waffenschmidt, S., Page, M. J., & Koffe, J. B. (2021). PRISMA-S: an extension to the PRISMA Statement for Reporting Literature Searches in Systematic Reviews. *Systematic Reviews*, 30, 385–386. https://doi.org/10.1007/978-3-642-71213-5_65
23. Tigges, M., Dräger, S., Piccini, I., Bieber, K., Vorobyev, A., Edelkamp, J., Bertolini, M., & Ludwig, R. J. (2025). Pemphigoid disease model systems for clinical translation. *Frontiers in Immunology*, 16(March), 1–25. <https://doi.org/10.3389/fimmu.2025.1537428>
24. Vičić, M., & Marinović, B. (2023). Autoimmune bullous diseases in pregnancy: an overview of pathogenesis, clinical presentations, diagnostics and available therapies. *Italian Journal of Dermatology and Venereology*, 158(2), 99–109. <https://doi.org/10.23736/S2784-8671.23.07553-9>
25. Waffenschmidt, S., Knelangen, M., Sieben, W., Bühn, S., & Pieper, D. (2019). Single screening versus conventional double screening for study selection in systematic reviews: A methodological systematic review. *BMC Medical Research Methodology*, 19(1), 1–9. <https://doi.org/10.1186/s12874-019-0782-0>
26. Xie, F., Davis, D. M. R., Baban, F., Johnson, E. F., Theiler, R. N., Todd, A., Pruneddu, S., Murase, J. E., Maul, J.-T., Ambros-Rudolph, C. M., & Lehman, J. S. (2023). Development and multicenter international validation of a diagnostic tool to differentiate between pemphigoid gestationis and polymorphic eruption of pregnancy. *Journal of the American Academy of Dermatology*, 89(1), 106–113. <https://doi.org/10.1016/j.jaad.2023.01.027>